

Anatomical study of the human anterior cruciate ligament stump's tibial insertion footprint

András Tállay · Mui-Hong Lim · John Bartlett

Received: 24 October 2007 / Accepted: 10 April 2008 / Published online: 15 May 2008
© Springer-Verlag 2008

Abstract The aim of this study is to define the topographical relationship of the anatomical bundles of the human anterior cruciate ligament's (ACL) stump over the tibial insertion site. Between January and April 2007, a total of 36 resected tibial plateaus were retrieved from patients who underwent total knee replacements. These samples had intact cruciate ligaments with no major osteophyte around the ACL tibial insertion footprint. The anatomical bundles of the ACL were identified and mapped, based on the topographical relationship over the tibial insertion footprint. Measurements of the dimensions of the ACL tibial footprint and tibial plateau were performed. The mean width and midsagittal depth of the tibia plateau was 78.7 ± 6.5 and 46.4 ± 5.0 mm, respectively. The mean width and midsagittal depth of the ACL tibial footprint was 10.3 ± 1.9 and 19.5 ± 2.6 mm, respectively. Out of the 36 freshly dissected ACL stumps, it was not possible to distinguish separate bundles in 14 (38.9%) cases. The average distance between the centers of the two bundles was 9.3 ± 1.8 mm. The mean AP alignment of the tibial footprint was $89.6^\circ \pm 26.4^\circ$, with a very wide range of 23° – 158° . Of the 22 specimens with separate anatomical bundles, the alignment of the tibial footprint was AM–PL in six (27.3%), sagittal (85° – 95°) in five (22.7%), AL–PM in nine (40.9%), and lateral–medial (L–M) in two (9.1%) cases. This study provides new information about the topographical anatomy of the ACL tibial insertion footprint. Based on gross anatomy, separate anatomical bundles of the ACL can be distinguished in 61.1% [22] of

the specimens. The topographical alignment of the separate bundles is varied on a very wide range.

Keywords ACL anatomy · Anteromedial bundle · Posterolateral bundle · Double-bundle · Tibial footprint

Introduction

Numerous studies have validated the good outcomes of intraarticular single-bundle anterior cruciate ligament (ACL) reconstruction [6]. Although single-bundle reconstructions have been successful in reducing the sagittal laxity, several investigators have questioned the ability of these reconstructions to control rotational instability and avoid the pivot-shift phenomenon. This is because single-bundle ACL reconstruction does not restore the complexity of the native double-bundle structured ACL [21]. Therefore it had been proposed and demonstrated that anatomical double-bundle ACL reconstruction can restore the knee joint kinematics, in particular, the restoration of rotational stability [11, 22]. Nonetheless, these were cadaveric based studies. To our knowledge, there is currently no clinical means to evaluate rotational stability.

Early descriptions on the two functional bundles of the ACL date back to an anatomical study performed by the Weber brothers in 1856 [19]. Since then, many anatomical and biomechanical studies have confirmed the “two bundle concept” [1–3, 10, 13, 16, 23]. Even though anatomical dissections suggest there may be even more bundles, most believe there are only two major functional bundles [1–3, 7, 10, 15, 23]. The historical terminology of the bundles is determined according to their tibial insertion, but the true topographical anatomy is not well documented. The fibers of the anteromedial (AM) insert at the anteromedial tibial

A. Tállay (✉) · M.-H. Lim · J. Bartlett
The Melbourne Knee Fellowship, Warringal Hospital,
1/210 Burgundy street, Melbourne, VIC, Australia
e-mail: tallay@t-online.hu

insertion, the fibers of the posterolateral (PL) bundle insert on the posterolateral part of the tibial insertion [10, 19]. On the basis of these findings, it has been suggested that both the AM and PL bundles should be reconstructed [25].

Various techniques of double-bundle reconstruction have been described with promising preliminary results [5, 6], however, there is no consensus to certain technical aspects of the reconstruction techniques [6, 26].

To perform the double-bundle technique, a better understanding of the bundle's attachment is essential. Although there have been studies on the bundles of the ACL [10], only limited studies on the topographical measurements of the insertions on the tibia of the AM and PL bundles of the ACL are available [4, 9, 10, 14]. All previous studies on ACL double-bundle anatomy only observed the two bundles under intact circumstances, and in histological studies [8] we could not find any data in the literature, whether it is possible to distinguish the bundles in the ACL stump, which is the normal situation during ACL reconstruction. This is a major limitation regarding guidelines for tunnel placement of double-bundle reconstruction.

We hypothesized that the AP alignment of the two bundles within the ACL tibial insertion area is not always in the AM–PL direction; therefore, finding the original anatomical position of the two bundles for double-bundle ACL reconstructions cannot be standardized.

The purpose of this study was therefore to describe and measure the anatomical–topographical position (sagittal alignment) of the tibial attachment area of the ACL stump focusing on the double-bundle reconstruction technique to facilitate more accurate tibial tunnel placement. Our purpose was to evaluate whether it is possible to distinguish the AM and PL bundles of the native ACL in the freshly dissected ACL stump.

Materials and methods

Between January and April 2007, a total of 36 resected tibial plateaus were retrieved from patients who underwent total knee replacements. The inclusion criteria of the study were specimens with intact ACL and PCL. The exclusion criteria were patients with ACL and/or PCL injuries, and specimens with major osteophyte formation around the tibial insertion area. Patients with underlying inflammatory arthritis and secondary arthritis were also excluded from the study.

During the knee replacement, with the knee flexed at 90° and the patella dislocated laterally, the intercondylar osteophytes and synovial covering were excised to visualize the cruciate ligaments. The dynamic kinematic pattern of the ACL's functional bundles was observed throughout the range of passive movement prior to

detachment from the femoral insertion site. The origin of the ACL and PCL was then sharply dissected from its femoral insertion. Following the tibial resection, the tibial plateaus were harvested. The ACL stump was dissected from the femoral end to the tibial footprint with the aim of defining the separate anatomical bundles and their insertional relationship over the tibial plateau. The ACL insertion footprint was outlined and the center of insertion of the respective bundles was marked. The center of the insertion site was defined as the insertion area of the central fibers of the respective bundles. The following measurements were recorded for all 36 specimens, using a manual Vernier caliper and computerized image mapping softwares (Adobe Illustrator CS3 Mac OSX©) (Fig. 1):

- 1 Midsagittal depth of the tibial plateau;
- 2 Maximum width of the tibial plateau in the coronal plane;
- 3 Midsagittal length of the ACL footprint;
- 4 Maximum width of the ACL footprint in the coronal plane;
- 5 Distance from anterior margin of the tibial plateau to the anterior margin the ACL footprint;
- 6 Distance between the centers of the separate ACL bundles;
- 7–8 Distance from anterior margin of the tibial plateau to the center of the separate ACL bundles;
- 9 Shape and sagittal orientation of the ACL footprint

The midsagittal depth of the tibial plateau was measured at right angle to the midpoint of the maximum width of the tibial plateau.

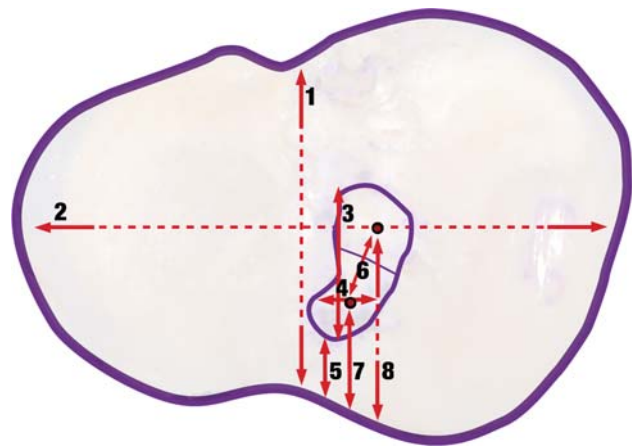


Fig. 1 Axial tibia view with tibial measurement distances. (1) Midsagittal depth of the tibial plateau; (2) Maximum width of the plateau in the coronal plane; (3) Midsagittal length of the ACL footprint; (4) Maximum width of the ACL footprint in the coronal plane; (5) Distance from anterior margin of the tibial plateau to the anterior margin the ACL footprint; (6) Distance between the centers of the separate ACL bundles; (7, 8) Distance from anterior margin of the tibial plateau to the centre of the separate ACL bundles

Each plateau with the marked attachment areas was photographed with a ruler positioned as a scale factor. All of the images were normalized to the same scale and adjusted so that they were all right-sided. The orientation of the tibial foot prints was measured by the computer using the Adobe Illustrator programme.

Results

The mean age of the 36 TKR patients was 67.3 ± 10 years. Sixty-one percent ($n = 22$) were female and the side of operation was equally distributed. The mean length of the tibia plateau in the coronal plane was 78.7 ± 6.5 mm; the mean midsagittal depth was 46.4 ± 5.0 mm. The mean length of ACL footprint was 19.5 ± 2.6 mm and the mean width was 10.3 ± 1.9 mm. The mean distance between the anterior border of the ACL and the anterior border of the tibia was 12.9 ± 2.8 mm. For the specimens that had distinct bundles, the mean distance between the centers of the two bundles was 9.3 ± 1.8 mm. The average distance of the centre of the AM bundle from the ventral tibia was 17.2 ± 4.1 mm. The average distance of the centre of the PM bundle from the ventral tibia was 25.6 ± 4.8 mm (Table 1).

Of the 36 freshly dissected ACL stumps, we were unable to define separate anatomical bundles in 14 (38.9%) cases. The orientation of the 22 tibias with the footprint of the two bundles was $89.6^\circ \pm 26.4^\circ$, with a very wide range of 23 – 158° (Fig. 2). Of the 22 specimens with separate anatomical bundles, the alignment of the tibial footprint was AM–PL in six (27.3%), sagittal (85 – 95°) in five (22.7%), AL–PM in nine (40.9%), and lateral–medial (L–M) in two (9.1%) cases.

Based on the description by Petersen and Zantop [17], we classified the shape of the footprint into two categories, triangular 8 (22.2%) and oval 28 (77.8%).

Discussion

With the current interest in anatomical double-bundle ACL reconstruction techniques, it is critical to have a thorough knowledge on the anatomy of the ACL. The anatomic form of the native tibial attachment still remains a particular concern for ACL reconstruction [4]. Based on our knowledge, there is limited literature describing the anatomy of the individual bundles attachment of the ACL [11, 12, 21, 23]. All previous authors of the anatomical papers evaluated the bundles and their insertions under intact ACL condition [10, 17]. There is no available data in the literature on how is it possible to distinguish the bundles in a chronic ACL stump.

Zantop et al. [24] were able to define the two bundles during arthroscopy in an intact ACL in all their cases, but there is no arthroscopic description of the tibial attachment area. Although most of the operative techniques suggest to place the drills just to the middle of the AM and PL bundles stump, we believe, it is not always possible under arthroscopic circumstances, because we were not able to distinguish the two bundles in 14 of the 36 freshly dissected ACL stumps. It means, in 38.9% of all ACL reconstructions it is impossible to follow Yasuda's advice [20, 21] for finding "just the middle of the AM and PL bundles". It correlates with our arthroscopic experience; it is not always possible to distinguish the two bundles in the ACL tibial stump.

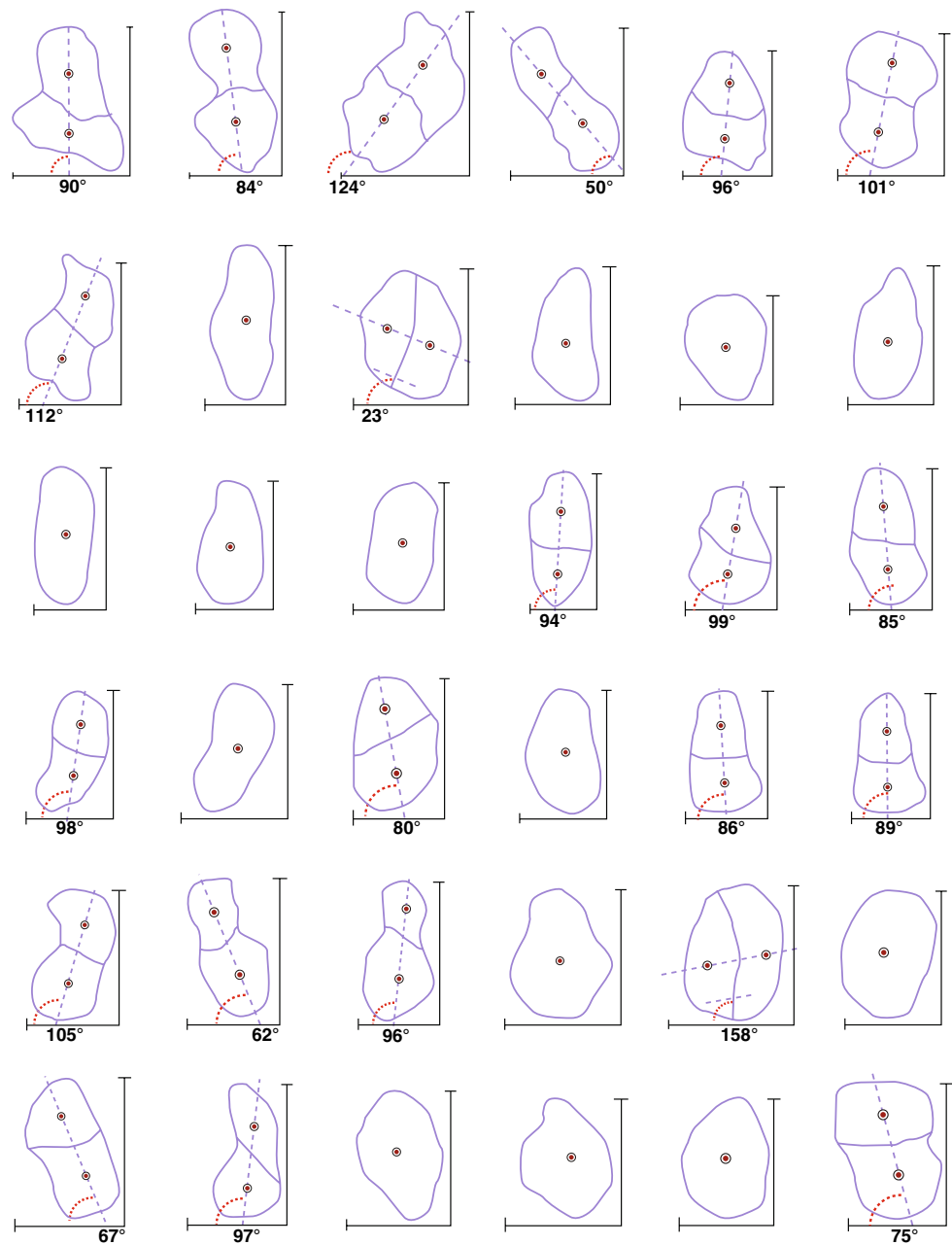To reproduce the native anatomy of the tibial attachment area, we need to know its shape, size, location, landmarks, and the AP orientation of the functional bundles as well.

Under arthroscopic circumstances in our experience it is impossible to determine the true shape of the tibial attachment area. Petersen and Zantop [17] reported that in most specimens the tibial insertion is triangular in shape, but in some specimens the tibial insertion can also be oval. It is a very subjective evaluation, but in our 36 specimens

Table 1 ACL tibial insertion measurements taken from for TKR resected tibial plateaus

Measurement	Average (mm)	Range (mm)
<i>n</i> = 36		
Midsagittal depth of the tibial plateau	46.4 ± 5.0	39.6–59.4
Max. width of the plateau in the coronal plane	78.7 ± 6.5	67.46–91.96
Midsagittal length of the ACL footprint	19.5 ± 2.6	14.5–24.7
Max. width of the ACL footprint in the coronal plane	10.3 ± 1.9	7.1–15.1
Distance from anterior margin of the tibial plateau to the anterior margin the ACL footprint	12.9 ± 2.8	7.4–20.5
<i>n</i> = 22		
Distance between the center of the separate ACL bundles	9.3 ± 1.8	6–12
Distance from anterior margin of the tibial plateau to the centre of the AM bundle	17.2 ± 4.1	10.4–23.8
Distance from anterior margin of the tibial plateau to the centre of the PL bundle	25.6 ± 4.8	15.1–35

Fig. 2 AP orientation and shape of the ACL tibial footprints. Angle less than 90° denotes an AM–PL orientation. Angle more than 90° denotes a PL–AM orientation



we found more oval (77.8%) than triangular (22.2%) footprints. The oblique tunnel entry in ACL reconstruction results in an oval footprint as well.

In our subjects we were able to measure accurately the size of the tibia and the ACL footprint. Our measured average ACL insertion length data (19.5 mm) is similar to those from other authors like Morgan et al. (18 mm) [13], Odensten and Gillquist (17.3 mm) [15], Colombet et al. (17.6 mm) [4, 13, 15], but differ from those of Girgis et al. (29.3 mm) [10], Staubli and Rauschnig (15 mm) [18]. We measured an average of 10.3 mm mediolateral width of tibial attachment, which is similar to those measured by Odensten and Gillquist (11 mm) [15], Morgan et al.

(10 mm) [13], slightly different from the data of Colombet et al. (12.7 mm). These data are important, to realize that the size of the bone tunnels should be adapted to the size of the knee. The AP length has clinical relevance regarding anatomic double-bundle reconstruction (native attachment area compared to the reconstructed attachment area). We should keep in mind there is a physiological impingement between the AM bundle and the anterior notch. The ACL fans out to form the foot region, which allows the ACL to tuck under the roof of the intercondylar notch [3, 16]. This specific anatomy causes concern for ACL reconstruction because grafts do not possess such a wrapping region. For this reason Arnoczky [3], already in 1983, recommended

that the tibial tunnel should not fill the tibial ACL attachment area anteriorly. It is well known that at the tibial side, the AM tunnel should be placed more anteriorly than a single tunnel, which means there is a higher chance for notch impingement. Therefore we believe that we have to distinguish the “anatomical insertion area” from the “surgical insertion area”, with average difference of 3–4 mm.

The literature provides only limited data about the separate insertions of the AM and PL bundles on the tibia [4]. We measured an average distance of 9.3 ± 1.8 mm between the geometrical centre of the two bundles, which is comparable to those from Colombet et al. [4] (8.4 ± 0.6 mm). Colombet et al. [4] described the “center” of each bundle attachment as “parallel projection” of the central fibers of the bundle onto its attachment (rather than the geometrical median of the attachment area). They believe that this best defines where the of the relevant tunnel should emerge into the joint. It seems to be rational, but is impossible to use in ACL stumps.

With the 8.3–9.4 mm distances between the centre of the two tunnels and with a need for a 2 mm bony bridge, we can conclude that the average combined diameter of the two tunnels cannot be more than 12–14 mm in an average size knee.

As a most reliable landmark for locating the centre of the AM and PL bundles Colombet et al. suggest to use the retro-eminence ridge. We found, our study material with minor osteophyte forming around the ACL attachment area is not accurate enough to determine anatomical landmarks, like the retro-eminence ridge from Colombet et al. [4], because of the degenerative or missing menisci we also could not use the anterior horn of the lateral or medial meniscus. As a landmark, we only measured the distances of the centre of the AM and PL bundles from the ventral tibia. According to our observations, the center of the AM bundle is located 17.2 ± 4.1 mm behind the anterior edge of the tibia. It is similar to those from Zantop et al. and Petersen et al. [16, 24], who found that a distance of 13–17 mm to the anterior edge of the tibia is aligned with the anterior horn of the lateral meniscus. The of the PL bundle is located in the posterior part of the tibial insertion. We measured an average of 25.6 ± 4.8 mm, which was comparable again to those from Zantop et al. and Petersen et al. [16, 24], with a distance of 20–25 mm. We tried to measure as a landmark the posterior border ACL–anterior margin PCL distances, but with an ACL and PCL stump, in our experience it was unreliable.

Giron et al. [11] described the topographical anatomy of the ACL tibial footprint. In his illustration of the 21 tibial ACL attachments, the varying shape and sagittal orientation of the individual footprints were noted, but not measured. In an unpublished study (Morris et al.), we

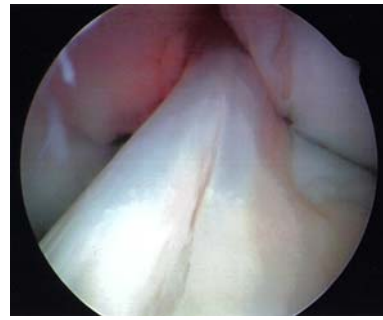


Fig. 3 Intact ACL with two bundles, see the insertion of the AM and PL bundles in this case is more medial to lateral than anteromedial–posterolateral

found similar results on arthroscopies with intact ACLs, the location of the two bundles are not always located AM–PL (Fig. 3). Although at the tibia the main concern has been the antero-posterior direction of the attachment area, until now, there was no data in the literature provided regarding the true AP alignment of the footprint.

The ACL surgeon must remember the diameter of the graft, thereby controlling medial–lateral placement of the bone tunnels. The usual AM graft size is 6–7 mm, the PL 5–6 mm [4], which means that the width of the original attachment area is always bigger than the size of the two tunnels; the question is about the medial–lateral topographic position of them. Petersen et al. suggest that both the bundles should be inserted in the middle of the tibia, but there were no measurements behind it [4]. A recently published study from Zhao et al. [26] suggests on the tibia a side by side localization to the two bundles: “the inner openings of both bundles were 7 mm anterior to the tip of the tibial spine and located on a medial–lateral line”. We found a similar side by side localization only in 9.1% of our study material; it is still a concern regarding the size of the tunnels.

Our hypothesis that the AP alignment of the two bundles within the ACL tibial insertion area is not always in the AM–PL direction has been proven. However, we are not able to give any guideline on how is it possible to find the original anatomical position of the two bundles for double-bundle ACL reconstructions.

We believe that this is the first investigation of the topographical anatomy of an ACL stump focusing on the natural AM and PL bundle attachments, which is the scenario of the reconstruction.

The principal limitations of this study were the age of the patients who were older than those patients who routinely undergo ACL reconstruction. In the arthritic knee, the anatomy of the ACL may differ from that of a nonarthritic knee; however; it is similar to previous studies [12, 13, 18]. We were unable to measure the intra- and inter-observer

variability, as the measurements were performed only once by a single observer (AT).

In summary, this study provides new data about the ACL stump's attachment topography and the shape specific to double-bundle ACL reconstruction that may facilitate more accurate tibial tunnel placement. In our study, we were able to provide new information about the orientation of the tibial footprints of the two functional bundles. However, one should keep in mind not every "double-bundle technique" seems to be "anatomical". Therefore, perhaps the term "anatomic ACL reconstruction" should only be used for techniques with the tunnel exactly at the surgical origin and insertion of the AM and PL bundle.

Historically, anteromedial and posterolateral are the two bundles based on the tibial attachment site, according to our anatomical study it is not recommended to be used routinely; we found it true in less than one-third of all cases.

Conflict of interest The authors report no conflict of interest.

References

- Amis AA, Dawkins GP (1991) Functional anatomy of the anterior cruciate ligament, Fibre bundle actions related to ligament replacements and injuries. *J Bone Joint Surg Br* 73:260–267
- Amis AA, Jakob RP (1998) Anterior cruciate ligament graft positioning, tensioning and twisting. *Knee Surg Sports Traumatol Arthrosc* 6(Suppl 1):S2–12
- Arnoczky SP (1983) Anatomy of the anterior cruciate ligament. *Clin Orthop Relat Res*:19–25
- Colombet P, Robinson J, Christel P, Franceschi JP, Djian P, Bellier G, Sbihi A (2006) Morphology of anterior cruciate ligament attachments for anatomic reconstruction: a cadaveric dissection and radiographic study. *Arthroscopy* 22:984–992
- Colombet P, Robinson J, Jambou S, Allard M, Bousquet V, de Lavigne C (2006) Two-bundle, four-tunnel anterior cruciate ligament reconstruction. *Knee Surg Sports Traumatol Arthrosc* 14:629–636
- Crawford C, Nyland J, Landes S, Jackson R, Chang HC, Nawab A, Caborn DN (2007) Anatomic double-bundle ACL reconstruction: a literature review. *Knee Surg Sports Traumatol Arthrosc* 15:946–964 discussion 945
- Dienst M, Burks RT, Greis PE (2002) Anatomy and biomechanics of the anterior cruciate ligament. *Orthop Clin North Am* 33:605–620
- Ferretti M, Levicoff EA, Macpherson TA, Moreland MS, Cohen M, Fu FH (2007) The fetal anterior cruciate ligament: an anatomic and histologic study. *Arthroscopy* 23:278–283
- Fuss FK (1989) Anatomy of the cruciate ligaments and their function in extension and flexion of the human knee joint. *Am J Anat* 184:165–176
- Girgis FG, Marshall JL, Monajem A (1975) The cruciate ligaments of the knee joint. Anatomical, functional and experimental analysis. *Clin Orthop Relat Res*:216–231
- Giron F, Cuomo P, Edwards A, Bull AM, Amis AA, Aglietti P (2007) Double-bundle "anatomic" anterior cruciate ligament reconstruction: a cadaveric study of tunnel positioning with a transtibial technique. *Arthroscopy* 23:7–13
- Harner CD, Baek GH, Vogrin TM, Carlin GJ, Kashiwaguchi S, Woo SL (1999) Quantitative analysis of human cruciate ligament insertions. *Arthroscopy* 15:741–749
- Morgan CD, Kalman VR, Grawl DM (1995) Definitive landmarks for reproducible tibial tunnel placement in anterior cruciate ligament reconstruction. *Arthroscopy* 11:275–288
- Norwood LA, Cross MJ (1979) Anterior cruciate ligament: functional anatomy of its bundles in rotatory instabilities. *Am J Sports Med* 7:23–26
- Odensten M, Gillquist J (1985) Functional anatomy of the anterior cruciate ligament and a rationale for reconstruction. *J Bone Joint Surg Am* 67:257–262
- Petersen W, Tillmann B (2002) Anatomy and function of the anterior cruciate ligament. *Orthopade* 31:710–718
- Petersen W, Zantop T (2007) Anatomy of the anterior cruciate ligament with regard to its two bundles. *Clin Orthop Relat Res* 454:35–47
- Staubli HU, Rauschnig W (1994) Tibial attachment area of the anterior cruciate ligament in the extended knee position, Anatomy and cryosections in vitro complemented by magnetic resonance arthrography in vivo. *Knee Surg Sports Traumatol Arthrosc* 2:138–146
- Weber W WE (1836) *Mechanik der menschlichen Gehwerkzeuge*. Dieterichsche Buchhandlung Göttingen
- Yasuda K, Konda E, Ichiyama H, Tanabe Y, Tohyama H (2005) Surgical and biomechanical concepts of anatomic anterior cruciate ligament anterior cruciate ligament reconstruction. *Oper Tech Orthop* 15:96–102
- Yasuda K, Kondo E, Ichiyama H, Kitamura N, Tanabe Y, Tohyama H, Minami A (2004) Anatomic reconstruction of the anteromedial and posterolateral bundles of the anterior cruciate ligament using hamstring tendon grafts. *Arthroscopy* 20:1015–1025
- Zantop T, Herbolt M, Raschke MJ, Fu FH, Petersen W (2007) The role of the anteromedial and posterolateral bundles of the anterior cruciate ligament in anterior tibial translation and internal rotation. *Am J Sports Med* 35:223–227
- Zantop T, Petersen W, Sekiya JK, Musahl V, Fu FH (2006) Anterior cruciate ligament anatomy and function relating to anatomical reconstruction. *Knee Surg Sports Traumatol Arthrosc* 14:982–992
- Zantop T, Petersen W, Fu F (2005) Anatomy of the anterior cruciate ligament. *Oper Tech Orthop* 15:20–28
- Zelle BA, Brucker PU, Feng MT, Fu FH (2006) Anatomical double-bundle anterior cruciate ligament reconstruction. *Sports Med* 36:99–108
- Zhao J, He Y, Wang J (2007) Double-bundle anterior cruciate ligament reconstruction: four versus eight strands of hamstring tendon graft. *Arthroscopy* 23:766–770